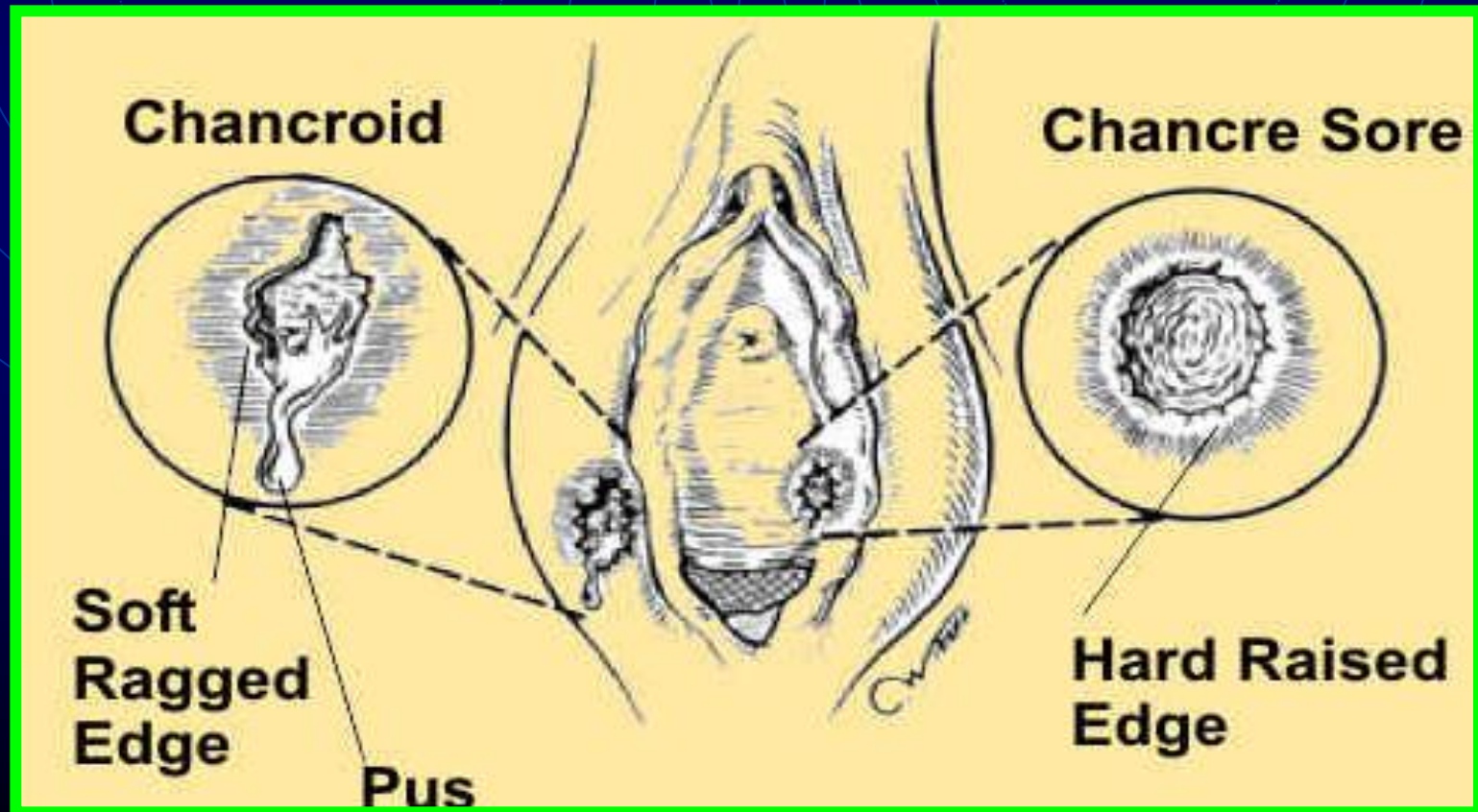
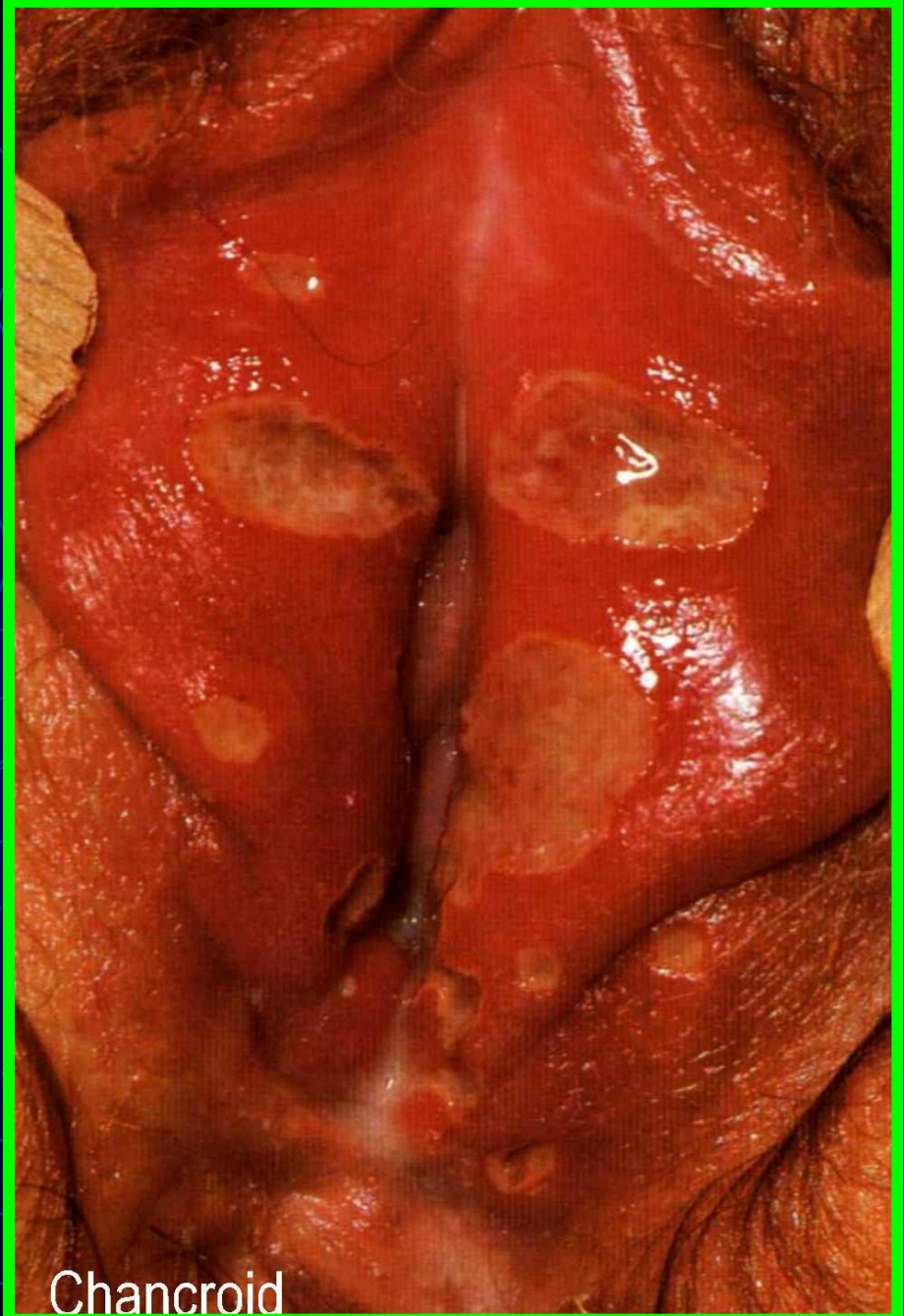
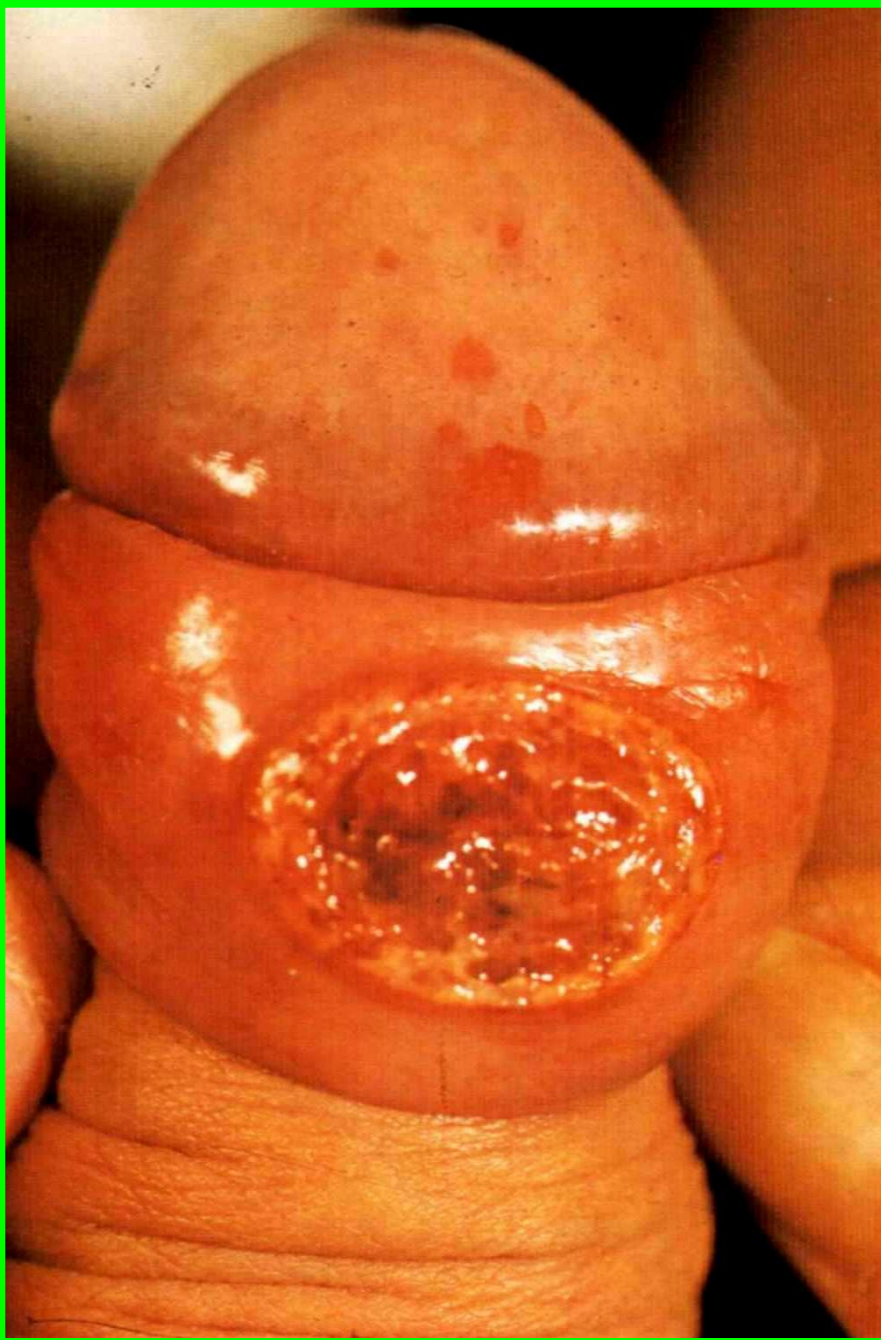


* Differential diagnosis:

1) **Chancroid:** multiple, soft, painful ulcers which bleeds easily, L N are enlarged matted painful and may suppurate





Chancroid

2) **Lymphogranuloma venereum** (the lesion is transient and disappear rapidly, L N are enlarged tender matted and may suppurate forming multiple sinuses and fistulae)

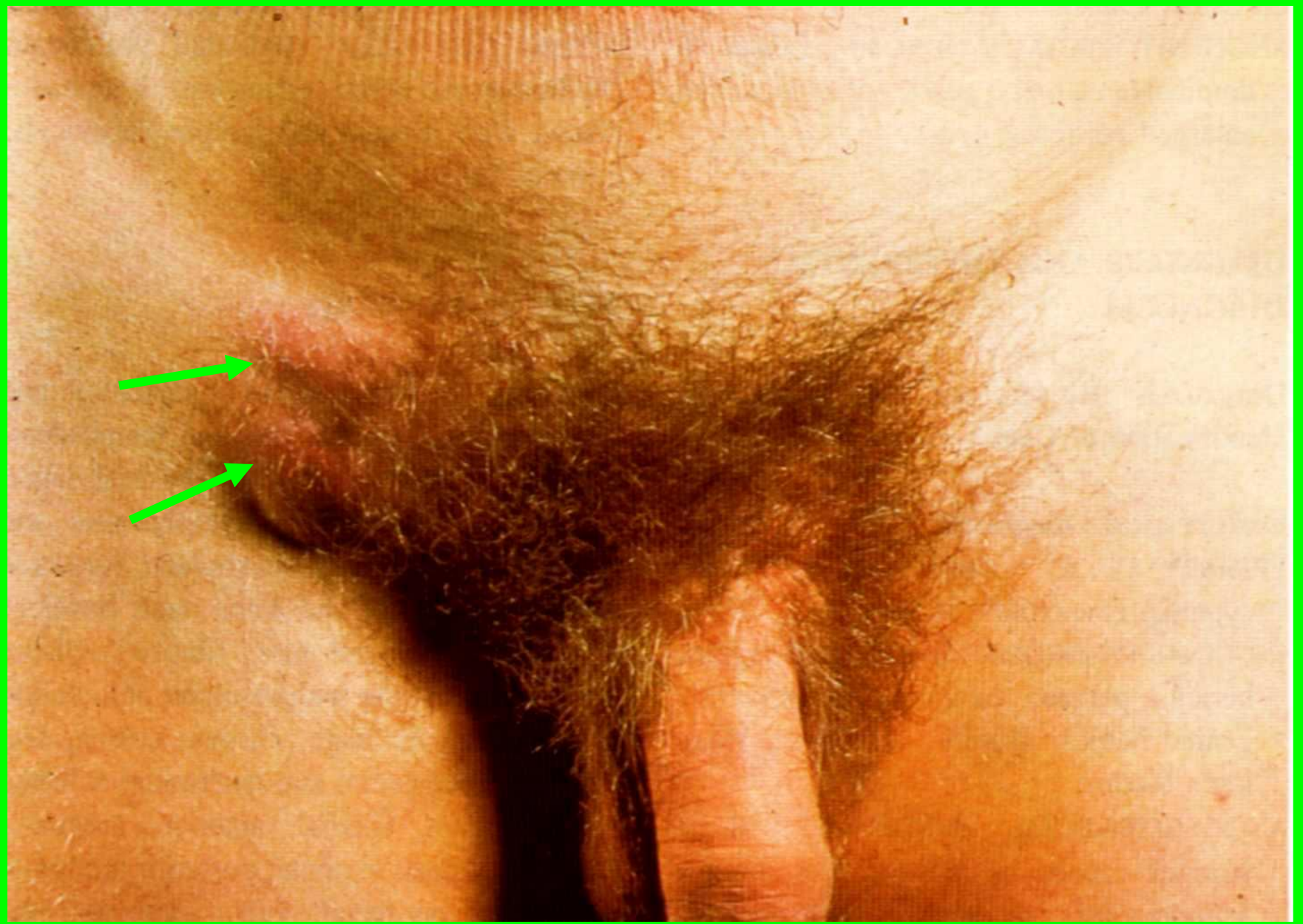3) **Genital herpes** (recurrent shallow painful ulcers)

4) **Traumatic ulcer**

5) **Pyogenic ulcer**

6) **Behcet's disease**

7) **Malignant ulcer**



Lymphogranuloma venereum