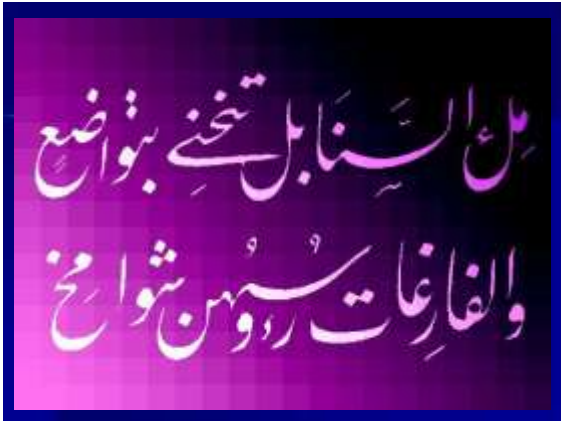

# SURGERY OF THE INTESTINE (2)

By

Alaa A. Radwan M.D, Ph.D

Prof. of Surgery & Laparoendoscopy



## Management of intestinal obstruction:

- \*-Gastro-intestinal decompression  
Methods????  
Benefits????
- \*-Fluid and electrolyte replacement
- \*-Relief of obstruction (? Surgery)

## Conservation ttt:

- (\*)-Suction improve respiration
  - preserve vitality
  - prevent vomiting
  - ↓absorption of toxic materials
  - facilitates operative procedure
  - ↓risk of post op. ileus

Ryle tube – Wangesteen & Levin tube – Miller-Abbott tube – Other tubes

## (\* ) Intravenous alimentation

- Correct dehydration
- Replace suction
- Maintain fluid & electrolyte

Saline – Glucose – Ringer lactates – Hyper.

(\* ) Antibiotics and chemotherapeutics

**(\*)-Conservative treatment**

**The sun should not both rise and set on a case of unrelieved intestinal obstruction**

**(\*)-Surgical exploration**

- \*- The site of obstruction
- \*- The nature of obstruction
- \*- The viability of intestine
- \*-Surgical decompression

**Colon resection**

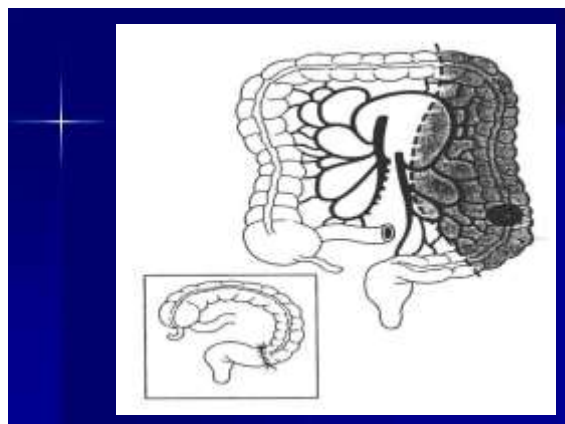
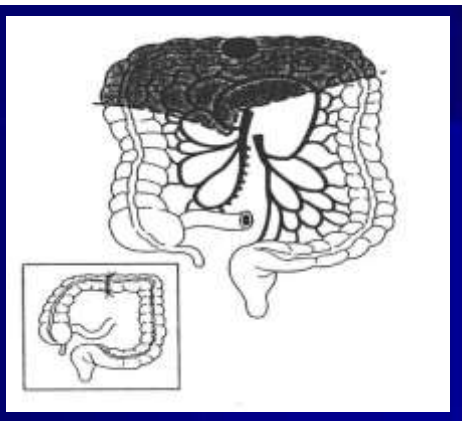
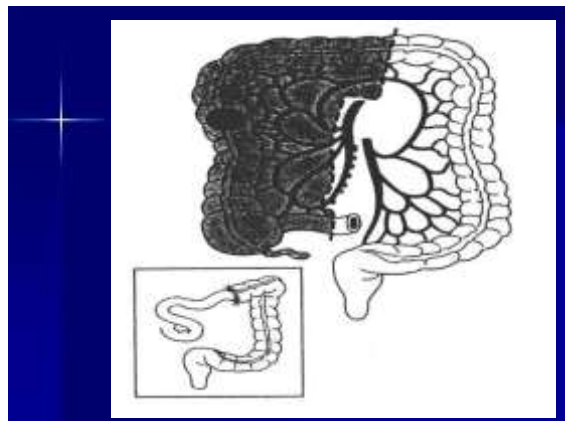
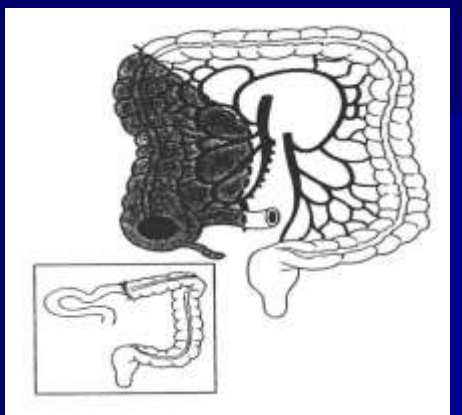
**Factors determining the management:**

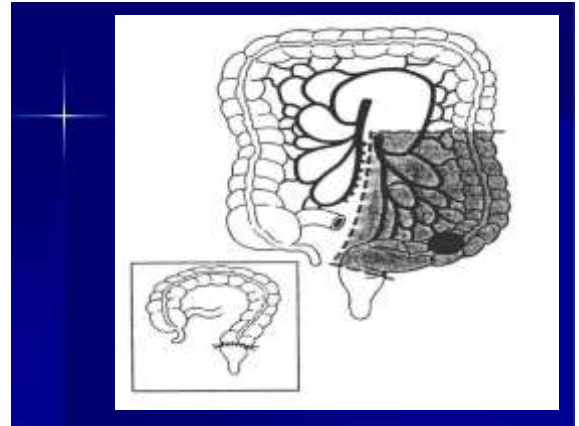
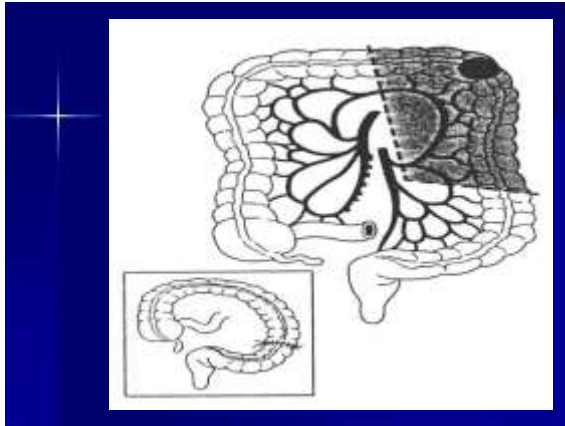
- (1) Blood supply. (2) Lymphatics.**
- (3) The content (4) Peritoneal covering.**

**Obstructed colon Vs non obstructed**

**Prepared colon Vs non prepared**

- \*-Mechanical preparation
- \*-Chemical preparation





**Simple occlusions:**

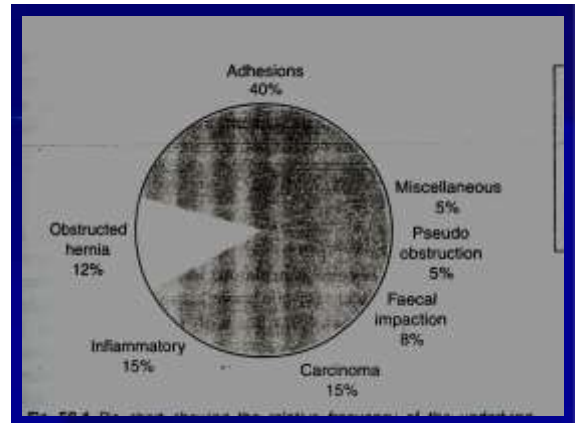
- \*- Atresia    \*- Bands & adhesions    \*- Obturations
- \*- Strictures    \*- Tumours

**Strangulations**

- \*- Str. Ext. hernia    \*- Intussusception    \*- Volvulus
- \*- Internal strangulation    \*- Mesenteric occlusion

**Neurogenic obstruction**

- \*- Paralytic ileus                      \*- Spastic ileus



**Bands and adhesions**

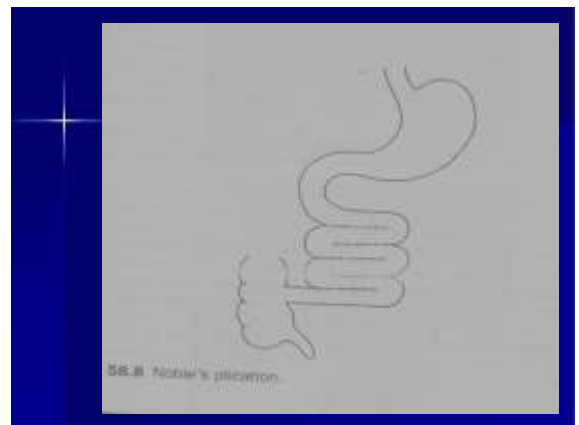- \*- Congenital                      \*- Acquired

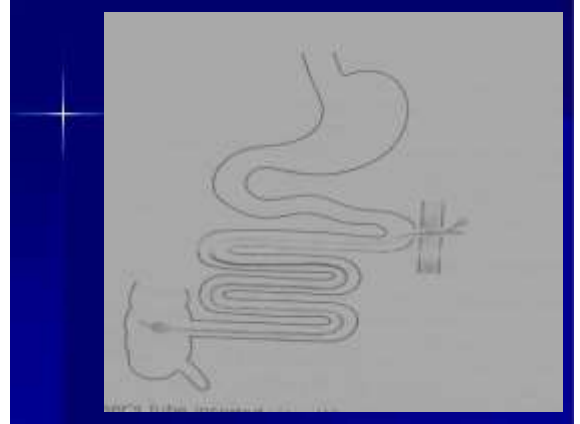
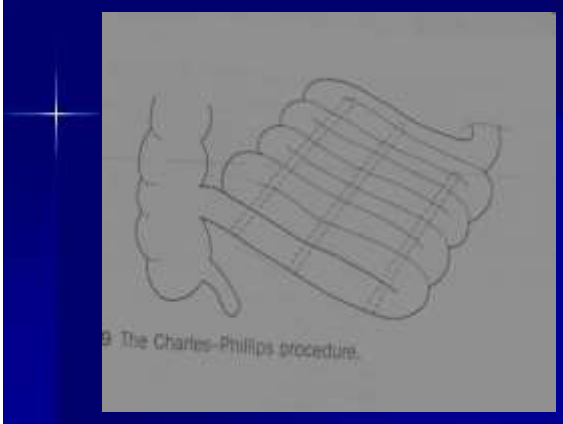
Clinical presentation

Diagnosis

Management ?? Conservation

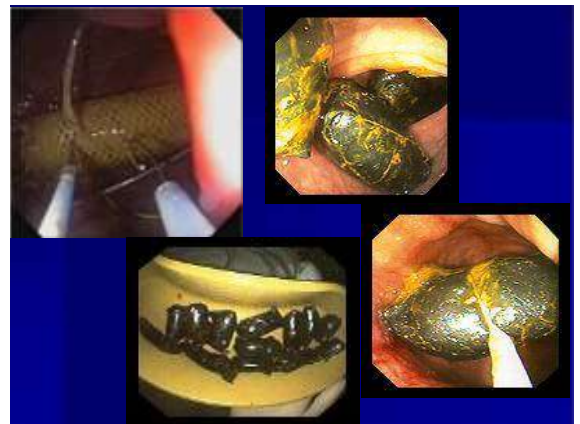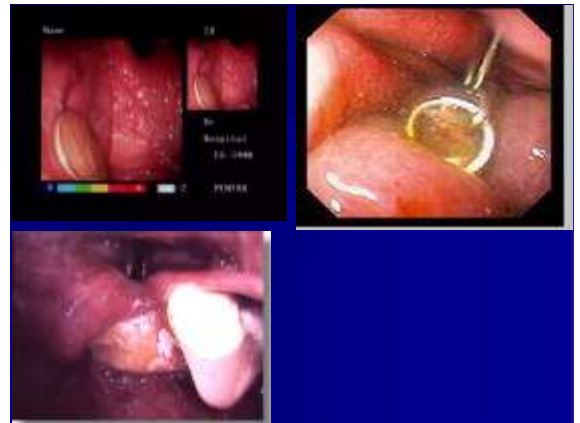Surgical options & hazards

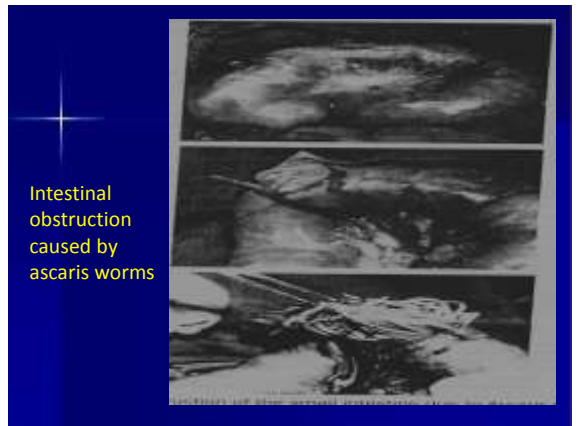
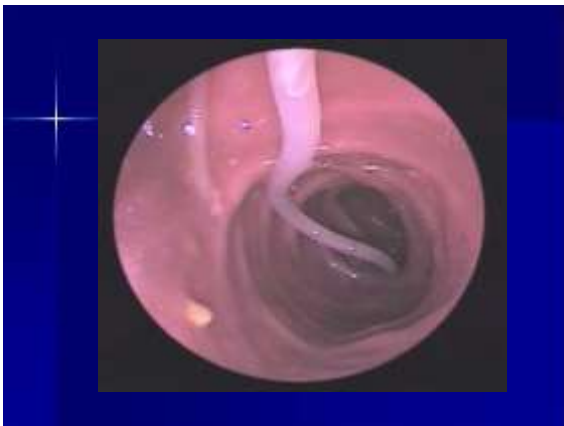
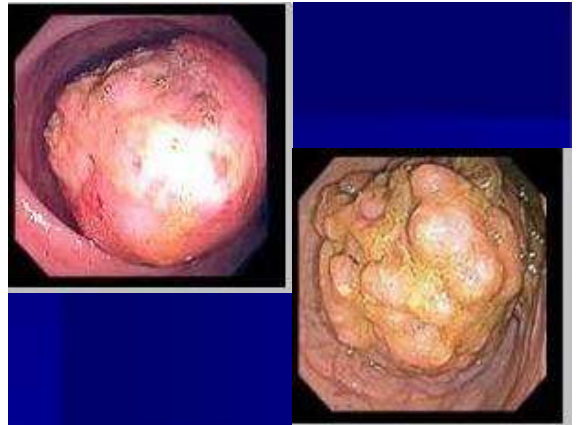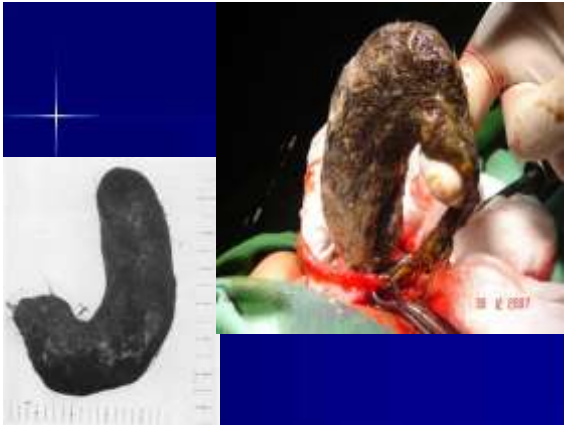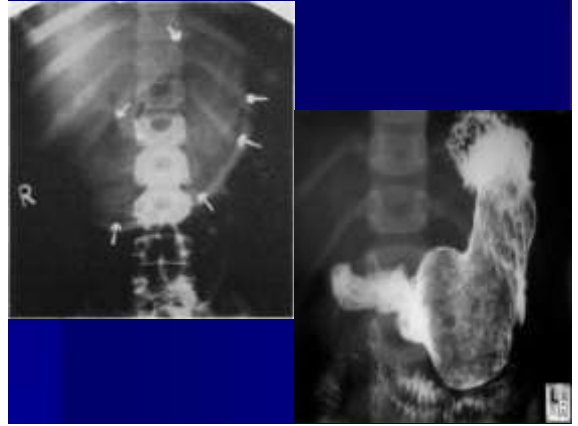
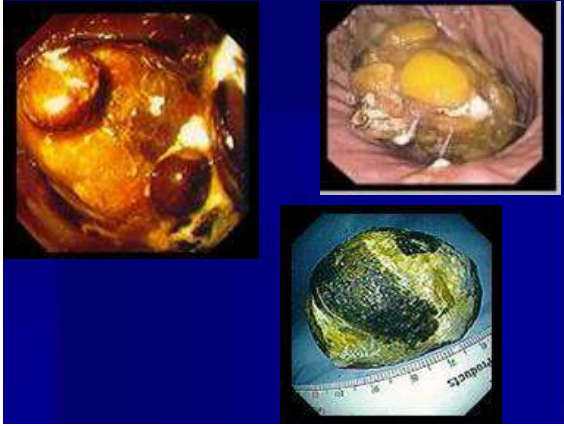




## Obturations

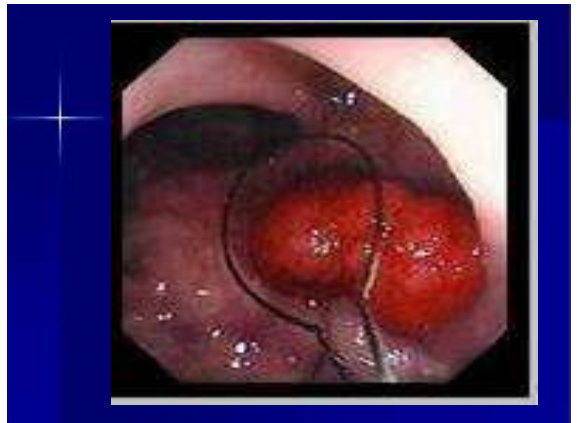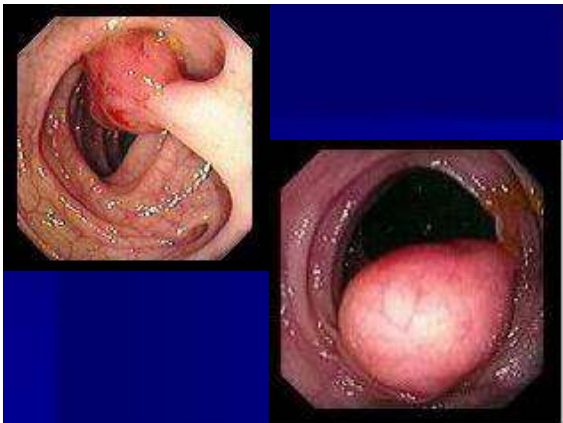
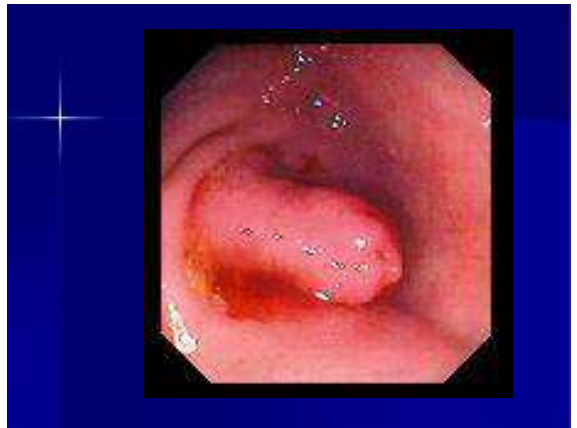- \*-Gall stone obturation
- \*-Enterolith obturation
- \*-Worms obturation
- \*-Foreign bodies obturation
- \*-Faecal impaction





## Intussusception

- (1) Infantile    acute
- (2) Adult        \*-acute
- \*-chronic
- \*-recurrent



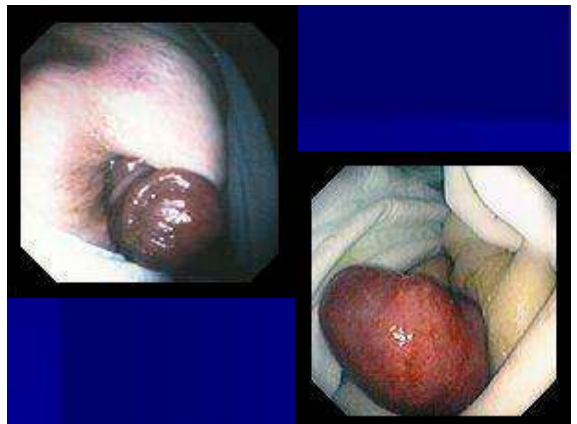## Infantile intussusception

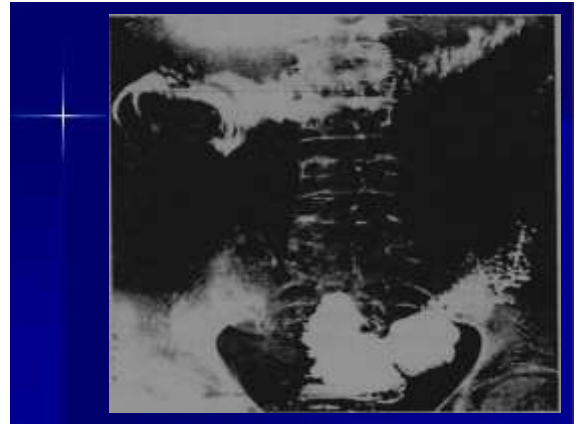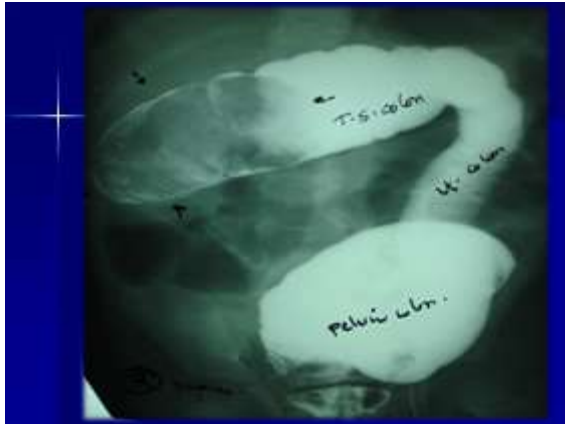
### Predisposing factors:

- \*Bulky ileo-caecal valve
- \*Mobile caecum and ascending colon
- \*Bulky bloodless fold of Treves
- \*Swollen lymphoid follicles
- \*Gastro-enteritis initiates irregular peristalsis

### Pathology:

ileo-ileal, ileo-caecal, ileo-colic, ileo-ileocaecal, colo-colic

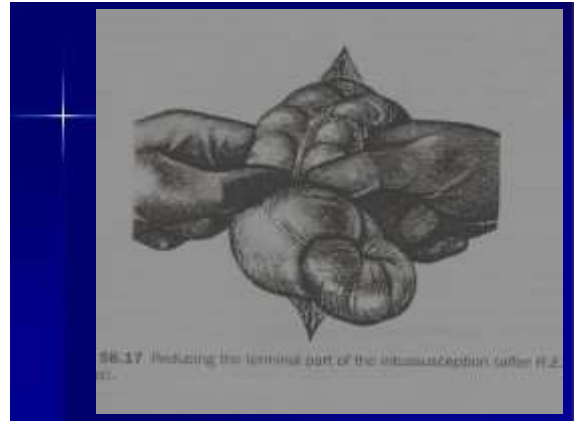



**D.D:** \*- Medical causes of abd. Pain & colic  
\*- Rectal prolapse

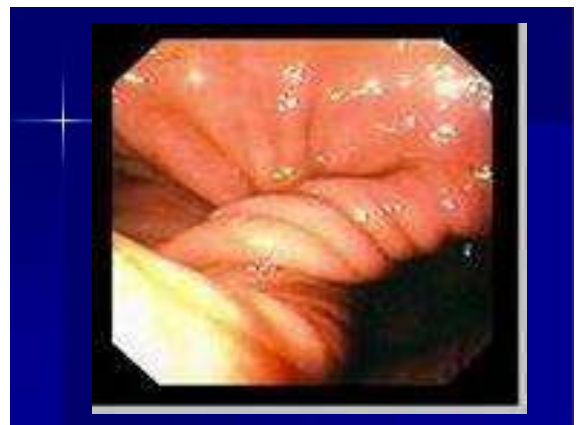**Treatment:** \*- Hydrostatic reduction  
\*- Operation reduction  
resection

Adult type: D.D  
Management



## Volvulus

- \*Volvulus stomach (ventro-axial, mesentrico-axial)
- \*Volvulus neonatorum (complete, arrested rotation)
- \*Volvulus of small intestine
- \*Volvulus of the caecum
- \*Volvulus of the Tve Colon:
- \*Sigmoid volvulus
- \*Snared loop volvulus
- \*Gall bladder volvulus (cong. mesentry)
- \*Appendix volvulus
- \*Other organs.



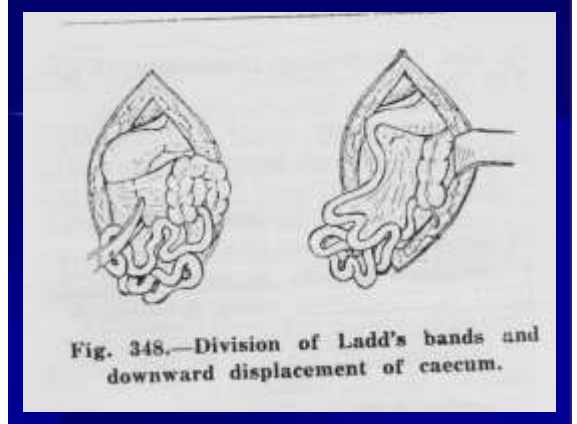
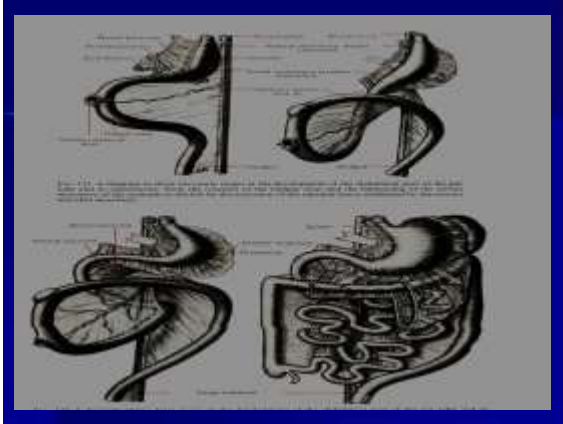
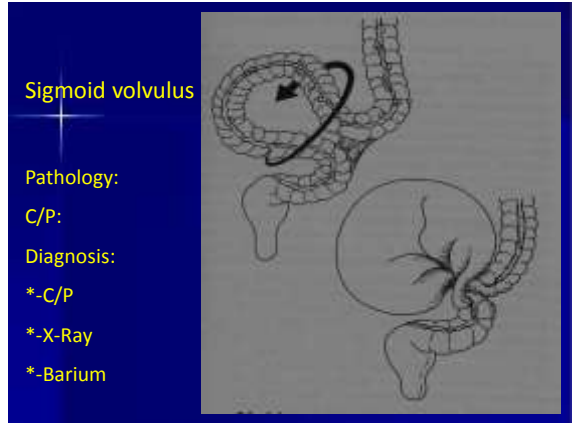
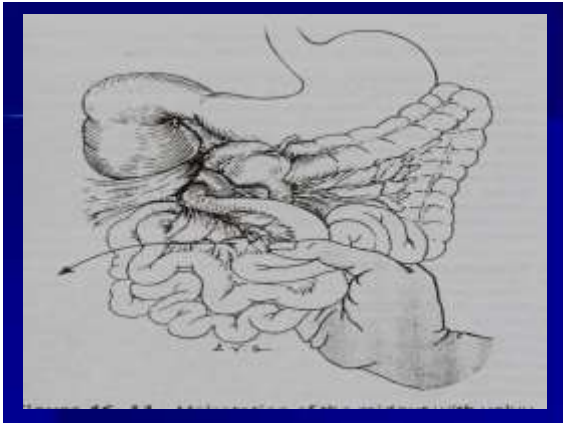

Fig. 348.—Division of Ladd's bands and downward displacement of caecum.



Sigmoid volvulus

Pathology:

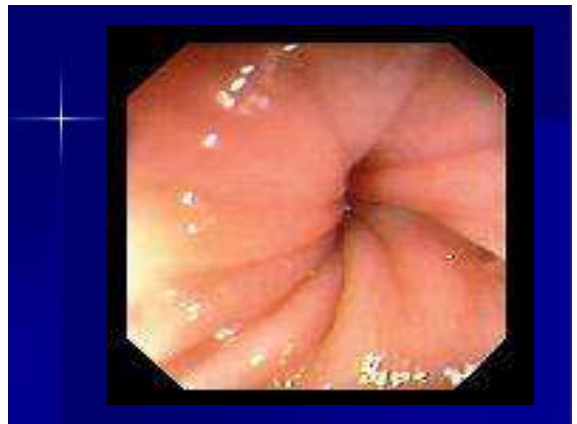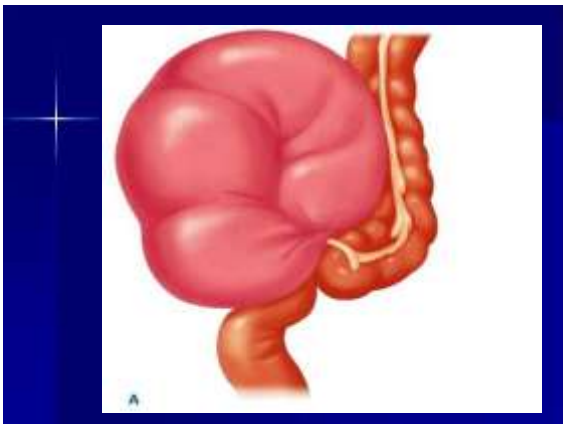
C/P:

Diagnosis:

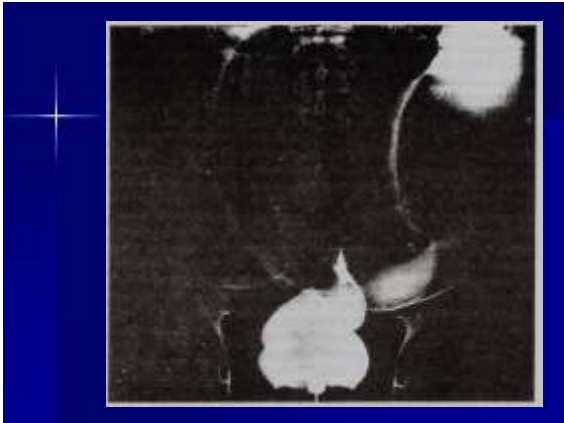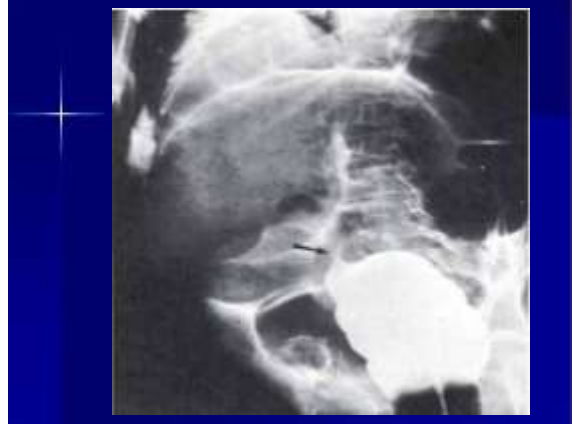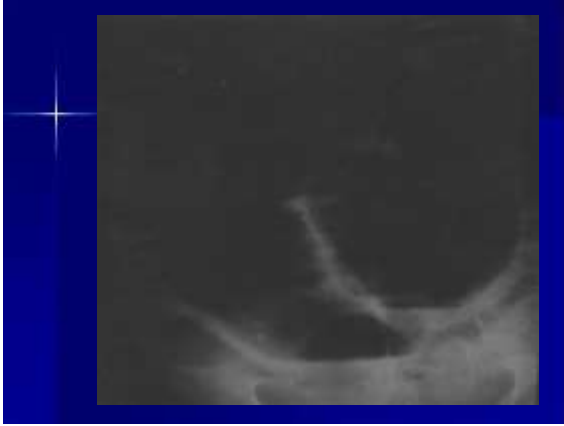
\*-C/P

\*-X-Ray

\*-Barium







Management:

- (I)-Conservative ttt
  - \*Enema
  - \*Scope
  - \*-Tube
- (II)-Surgical ttt
  - \*-Untwist ttt
  - \*-Resection ttt

