
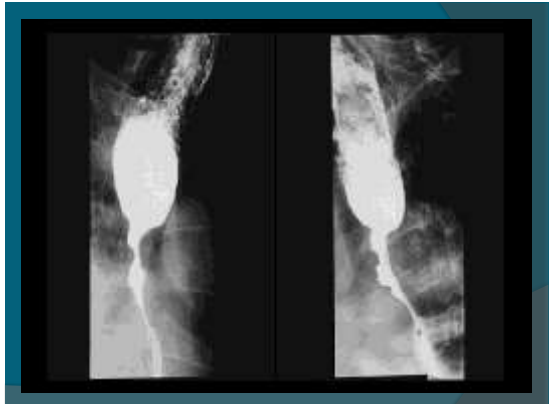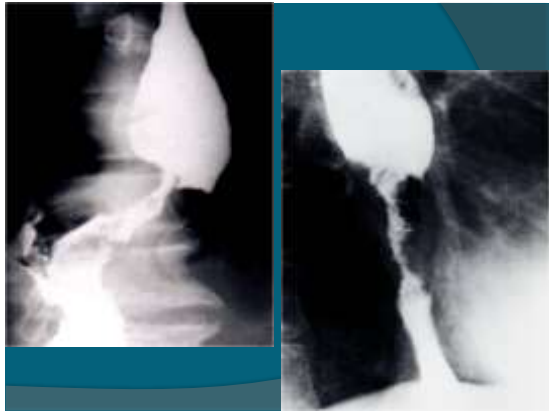
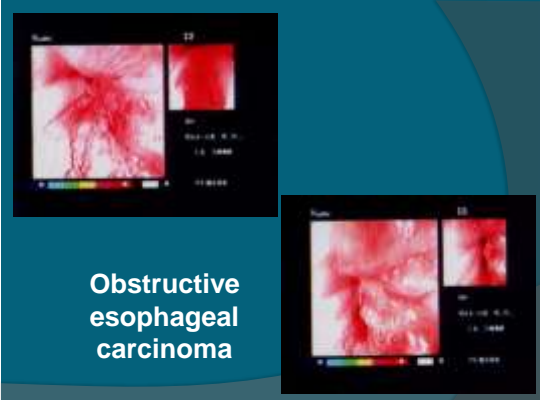


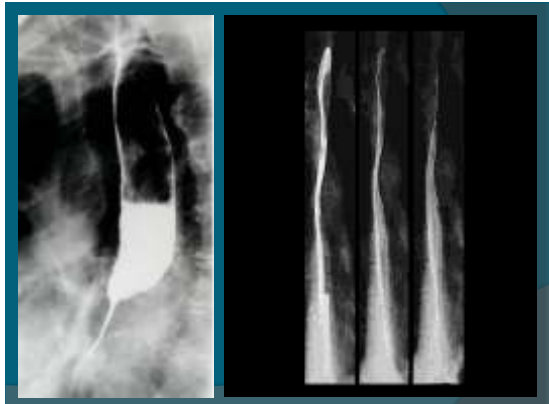
Boston Scientific Endoscopy

**Principles and Techniques of Endoscopic Stenting**

By  
**Prof. Alaa A. Redwan M.D., Ph.D**  
 Prof. of Surgery & Laparo-endoscopy  
 Sohag University Hospitals






**Obstructive esophageal carcinoma**



### History of Esophageal Intubation

- 1845 **Leroy d'Etoilles**  
Ivory tube (unsuccessful)
- 1885 **Sir Charles Symonds**  
Drainage tube
- 1955 **Coyas A.**  
First plastic prosthesis
- 1959 **Celestin LR**  
Plastic prosthesis at laparotomy

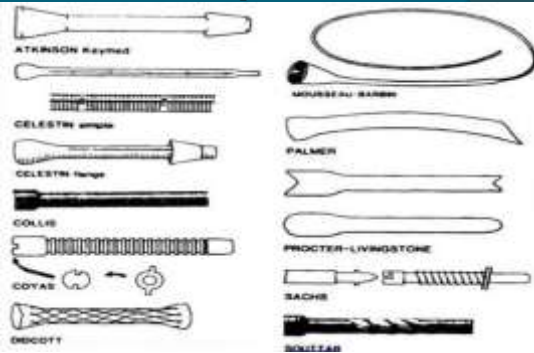


### History of esophageal intubation

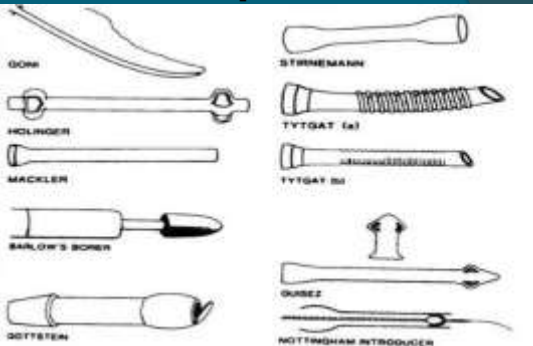
1978 Atkinson M  
1978 Endoscopically inserted plastic prosthesis



### Plastic prosthesis



### Plastic prosthesis




### Plastic prosthesis



### Drawbacks of Plastic Prosthesis


- ❑ Need of preparatory dilatation (2-4 Fr larger)
- ❑ Rigid tubes
- ❑ Small lumen ( liquid diet)
- ❑ Complications (up to 40%)
  - Perforation 5-10%
  - Hemorrhage 1-5%
  - Dislodgement 11-20%
  - Pressure necrosis 1-3%
  - Occlusion 5-10%
- ❑ Procedure related mortality 2-16%



**1969**



**Starting the Era of**


**Interventional Radiology**



**Charles Dotter**  
**1969**

**Coil Spring Endarterial Tube Graft**  
**(not expandable)**




## Nitinol

- **Shaped Memory Alloy (SMA)**: alloy that can be heat treated to remember a particular shape
- In 1961 William Beuhler, working at the US Naval labs, discovered the SM effect in an alloy of nickel and titanium
- **Ni** (chel)
- **Ti** (tanium)
- **N** (aval)
- **O** (rdinance)
- **L** (aboratory)


**NiTiAl Shape Setting**





## Nitinol

- Nitinol **contracts when heated**, which is the opposite of what standard metals do when heated (expand).
- The composition is typically 55-56% nickel and 44-45% titanium




Physical Properties


Tensile Strength 200,000 psi

Melting Point 1,250C (2,282 F)

Resistance 1.25 ohms per inch (.006 wire)

Corrosion Resistant







## Nitinol

**LIVE WIRE**

— FUN • EDUCATIONAL • SCIENTIFIC —






- Put in cold water
- Bend into crazy shapes
- Put in hot water
- It pops back straight again



**Charles Dotter - Andrew Cragg**  
**1983**

**Nitinol Spirals (Coils)**  
**(expandable)**



**Cesare Gianturco  
Julio Palmaz  
Hans Wallsten  
1985**

**Wallstent (Medivent)**

Hans Wallsten

Wallstent

**Why "Stent"?**

In 1856, the English dentist Charles Stent developed a thermoplastic-like material for taking impressions of toothless mouths

This "Stent mass" was later used for keeping a skin graft in place

Today the term "stent" indicates a tubular structure that maintains the lumen patency

Charles T. Stent (1885-1807)

**First Coronary Wallstent Implant  
March 28, 1986**

Pr. Jacques Paule  
Hôpital de Rangueil  
(Toulouse)

(66 y man who today is 86)

**First Internal Report on the Stenting Procedures in 1987**

<b>Vascular</b>	
Coronary	150
Peripheral iliac	40
SFA	100
Others	50
Total peripheral	190
<b>Non-vascular</b>	
Biliary	50
Urethral strictures	20
Urethra prostate	0
Total non-vascular	70
<b>Total patients</b>	<b>1125</b>

**Gastrointestinal and Biliary Stents**


- Stainless Steel
- Nitinol
- Plastic (Silicone)

**EsophaCoil™ Self-expanding Esophageal Stent...**

Easy and precise placement with topical anesthesia. Designed to resist ingrowth.



Tapered tip follows location through tight stenosis



**Stent's Wire Meshes**



**Stent's Wire Meshes**



**Stent's Wire Meshes**



**Stent's Covering**



### Esophageal Z•25™ Endoprosthesis System



Used to maintain patency of malignant esophageal strictures and to seal tracheoesophageal fistulas. The Wilson-Cook Esophageal Z-Stent Introduction System is used to place the Esophageal Z-Stent. These devices and components are supplied non-sterile and are disposable—intended for single use only.

### Esophageal Z-Stent™ with Uncoated Flange Ends

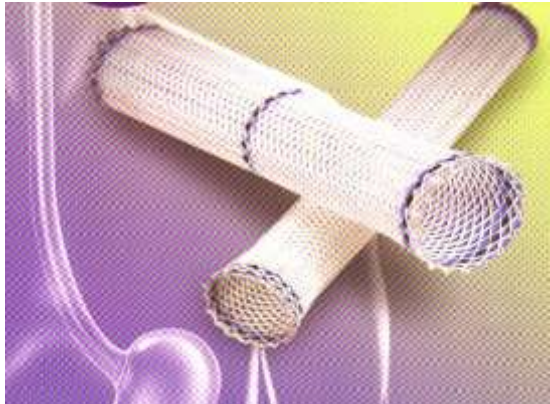
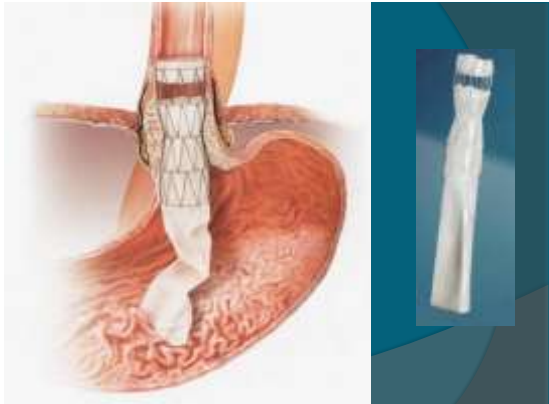
The uncoated, 25 mm flanged ends of this Esophageal Z-Stent allow greater anchoring of stent into the mucosa, decreasing risk of migration.

### Esophageal Z-Stent™ with Anchors



The central fixation anchors of this Esophageal Z-Stent facilitate stabilization within the esophagus, reducing the possibility of stent migration.



### Birth of "Stentotherapeutics"

- Radiation therapy
- Bioabsorbable
- Removable
- Drug delivery

## Physical Properties Of Stents

### Expansile Force and Buckling Radius of metal stents

Metal stents	Expansile force (N/mm/cm)	Buckling radius (mm)
Esophacoil	63.5	22
Wallstent	0.748	30
Z- stent	0.383	<200
Song	0.377	<200
Ultraflex	0.945	41

Chan ACW. Gastrointest Endosc 1999; 49: 462-465.

## Stents and MR

Only stainless steel stents undergo an appreciable attraction force and torque and cause gross artifacts on Magnetic Resonance imaging


Taal BG et al. Gastrointest Endosc 1997;46:424-429.

## Type of Stent Release

Through The Scope (TTS)

Over The Wire (OTW)

## Through The Scope (TTS) Stents



- Catheter outer diameter < 10.5 Fr
- $\geq 3.7$  mm channel scope required
- Direct Endoscopic control of stent release

## Over The Wire (OTW) Stents



- Catheter outer diameter > 10.5 Fr
- Require previous guide wire release

## Stent Insertion Technique

### I - Choice Of The Stent

According to:

- Stricture location
- Characteristics of the stricture
- Release system

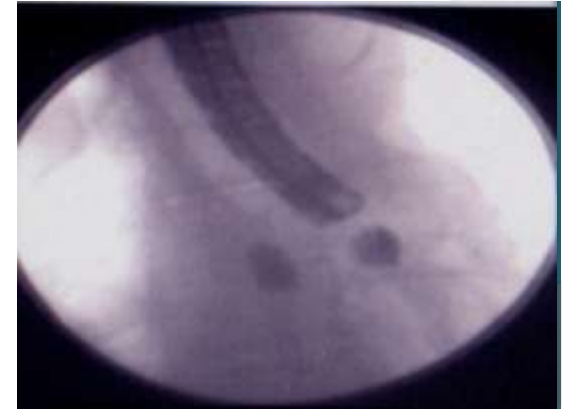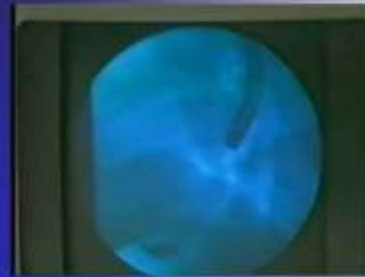## Stent Insertion Technique

### II - Tumor markers

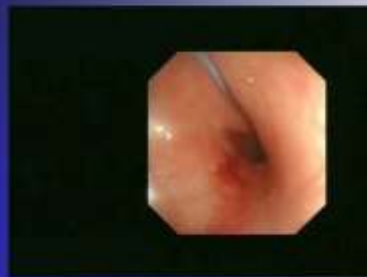- Radio-opaque markers placed externally on the skin
- Lipiodol injection
- Clips



## Lipiodol Markers



## Clips Markers



## Stent Insertion Technique

### III – Position the Guide wire beyond the stricture

#### (If tight stricture – TTS & OTW)

- Try to pass the stricture with a soft hydrophilic wire (Terumo, Jagwire) over a 6Fr catheter
- Once the wire has negotiated the stricture, advance the catheter beyond the stricture and change the wire with a stiff one
- In the colon: inject contrast to be sure to be in the lumen



## Stent Insertion Technique

### III – Position the Guide wire beyond the stricture


#### (If stricture not tight - OTW)

- Try to pass the stricture with a thin endoscope (5-6 mm) or a standard gastro-scope (colon)
- Release a stiff wire beyond the stricture (Savary, Terumo stiff, Jag wire, Amplatz ...)



**Stent Insertion Technique**

**IV – Measure the stricture length**



**Stent Insertion Technique**

**V – Dilate the stricture (If strictly necessary)**

- Dilate up to few Fr over the delivery system diameter



**Balloon dilation of stricture**

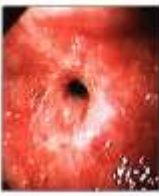

Figure 1

A 70-year-old woman presented with intermittent dysphagia over the last few months. She had a long history of gastro-oesophageal reflux, but had experienced no weight loss or vomiting. There had been no prior oesophagectomy.

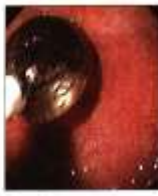

Figure 2

Endoscopy revealed a fibrotic, benign stenosis 3 cm from the incisors, approximately 3 mm in diameter (Figure 1).

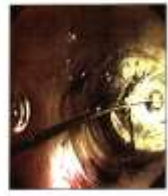

Figure 3

The 12-11.5 Fr (Stent CRE) balloon was placed in the stricture (Figure 2 and 3) and dilated at stepwise increments at the recommended pressure (Figure 4, 5, and 6). The procedure was easily tolerated by the patient, without complications, using only fluoroscopic analysis.

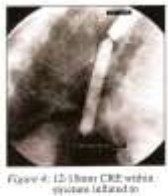

Figure 4: 12 Fr (Stent CRE) inflated to 12 Fr.

Fluorographic water column to illustrate the success of the balloon throughout this procedure. After the dilation, the length of the stricture was assessed

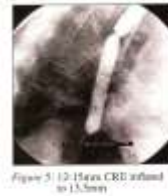

Figure 5: 12-15 Fr (Stent CRE) inflated to 15 Fr.

to be less than 2 cm (Figure 7). Upon successful procedural results, the patient was given symptomatic anal therapy with proton pump inhibitors.

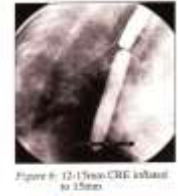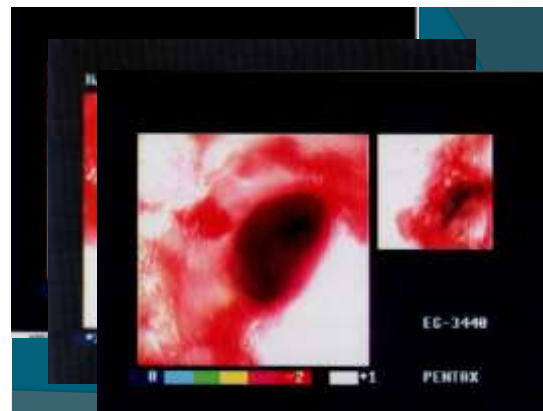
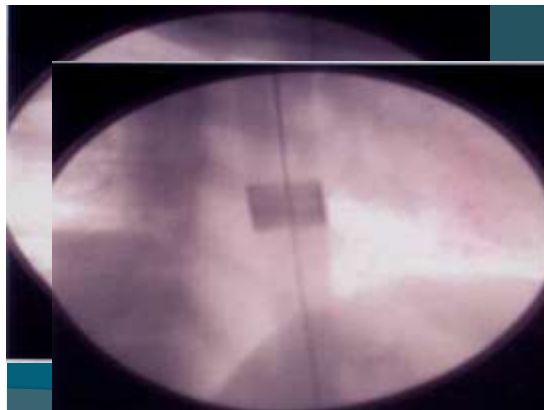
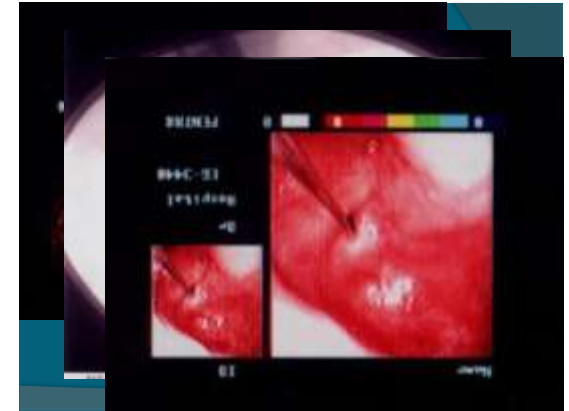


Figure 6: 12-18 Fr (Stent CRE) inflated to 18 Fr.

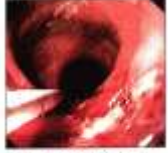
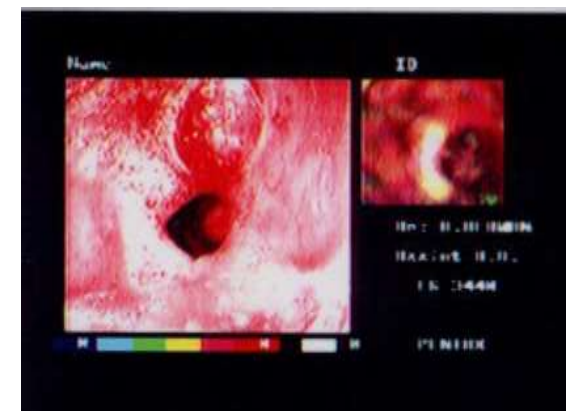
Figure 7: Post-dilatation, fully open lumen.

# Savary dilation of strictures



### Stent Insertion Technique

#### VI – Select stent length

- The stent must always be 4 – 6 cm longer than the stenosis, so that it extends at least 2 – 3 cm at both ends of the stenosis, thus minimizing the risk of tumor overgrowth



### Stent Insertion Technique

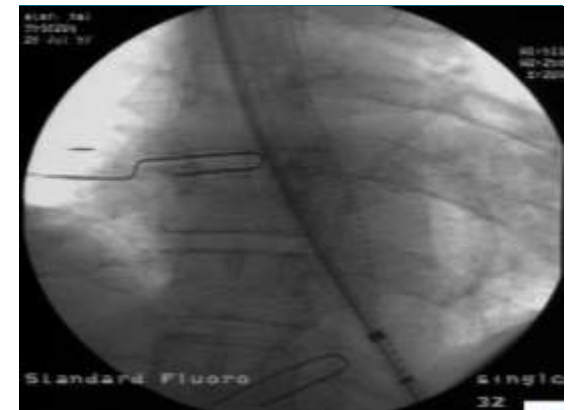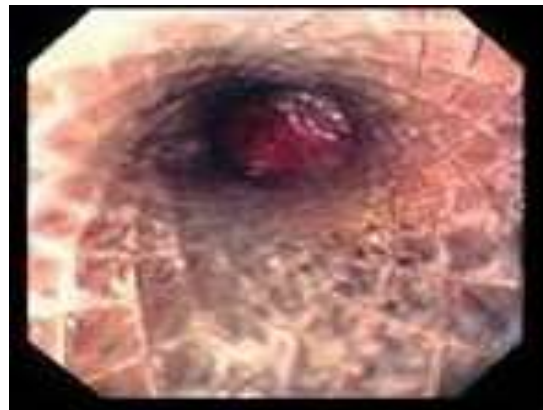
#### VI – Stent Release

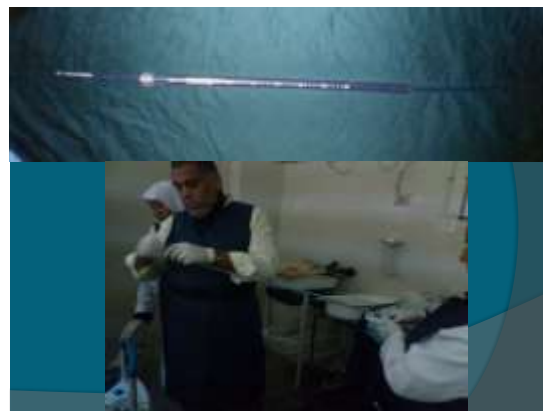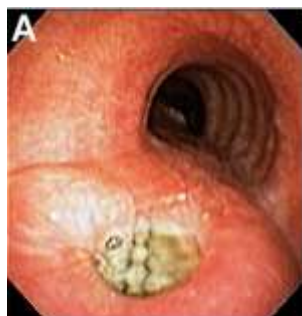
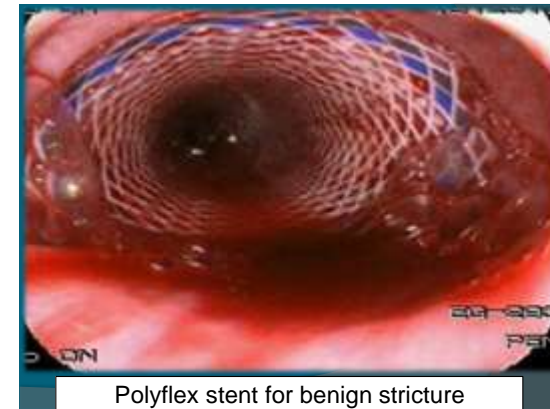
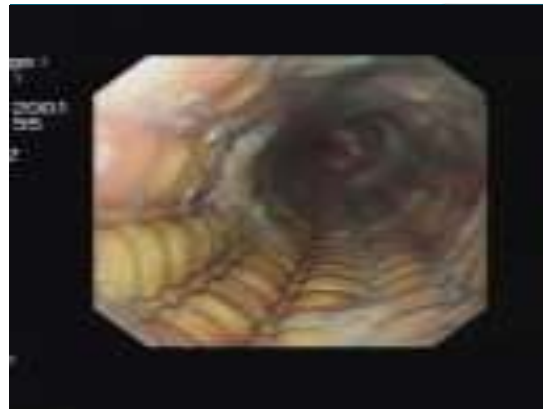
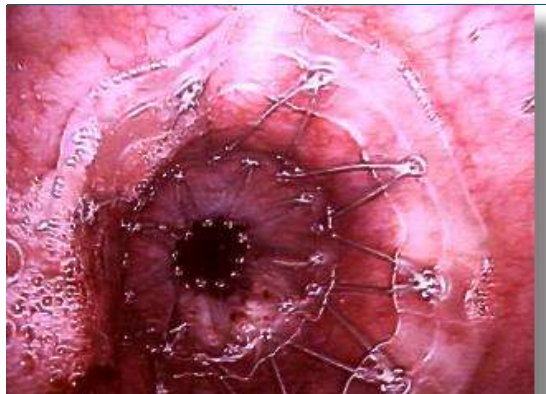
- Slow release under fluoroscopic control (marker's position)
- With Proximal Release OTW stents (Ultraflex Esophageal and Precision) use endoscopic control alongside the catheter
- A randomized trial of endoscopic versus radiologic insertion of metal stents has never been performed

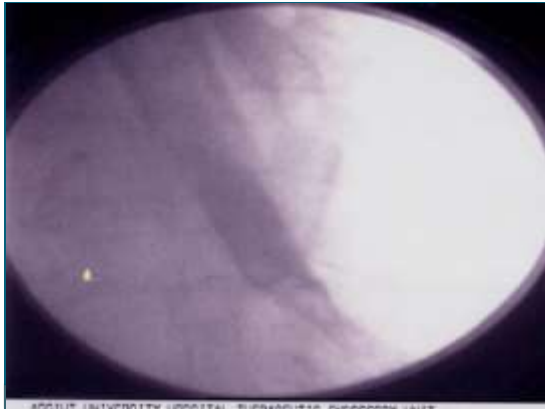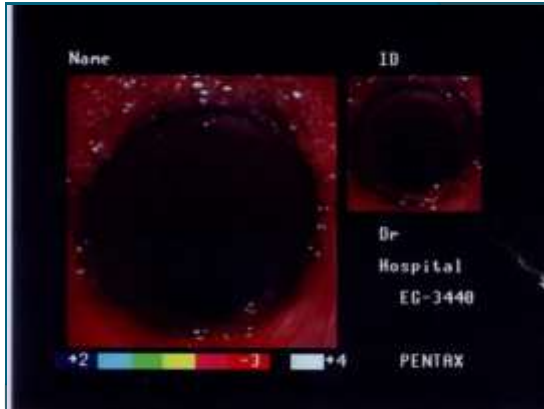
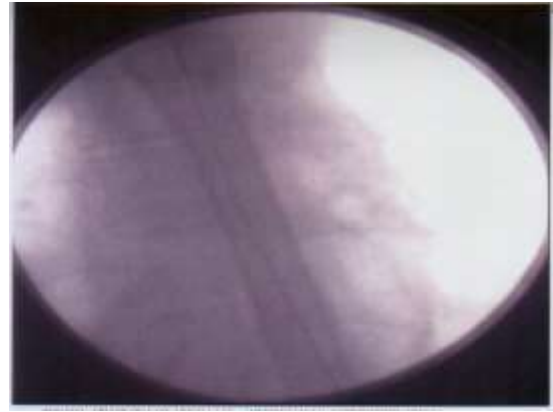
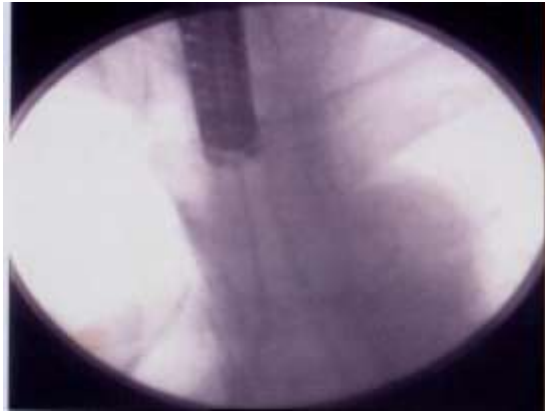
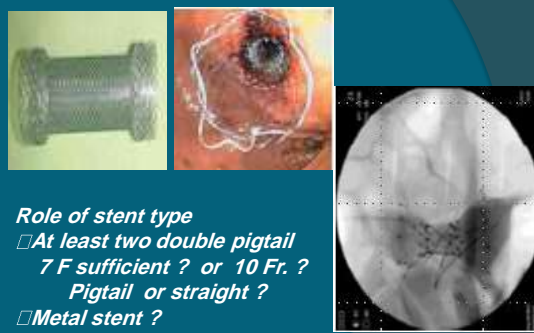


### Stent Insertion Technique

#### VI – Stent Release





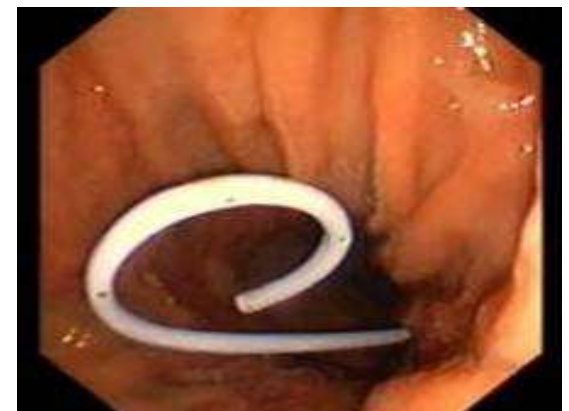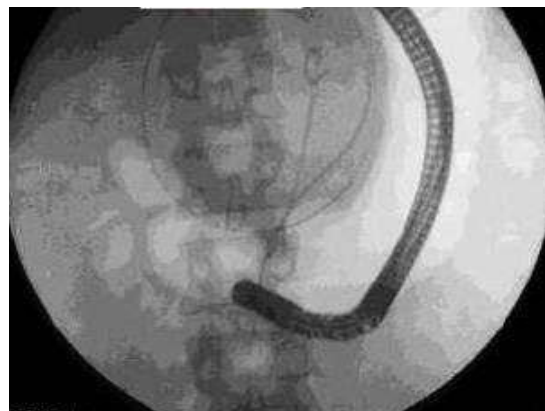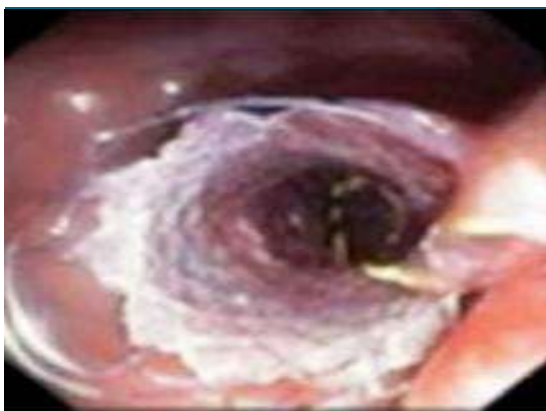
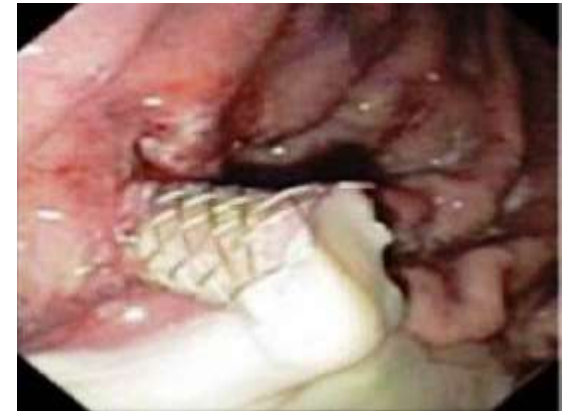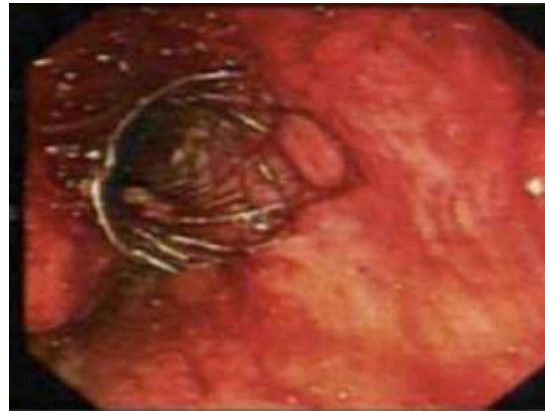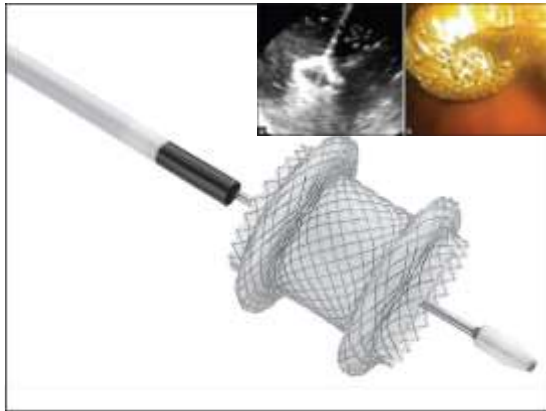



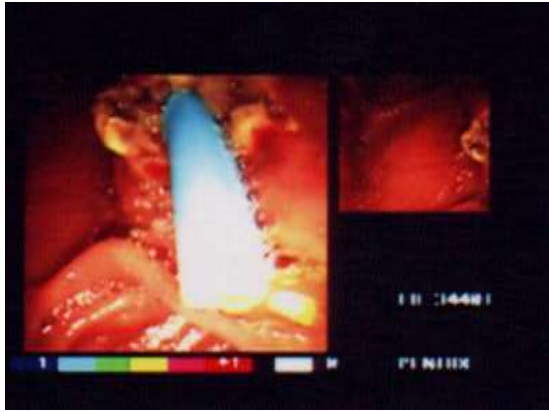
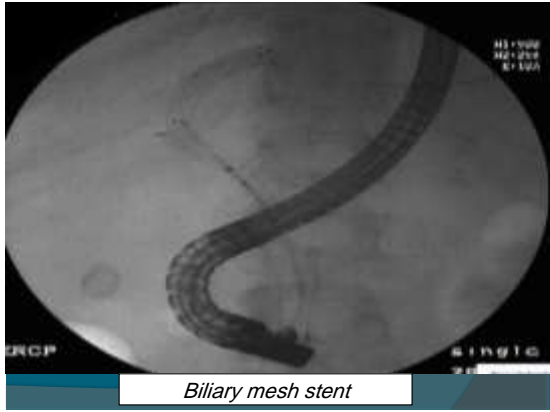
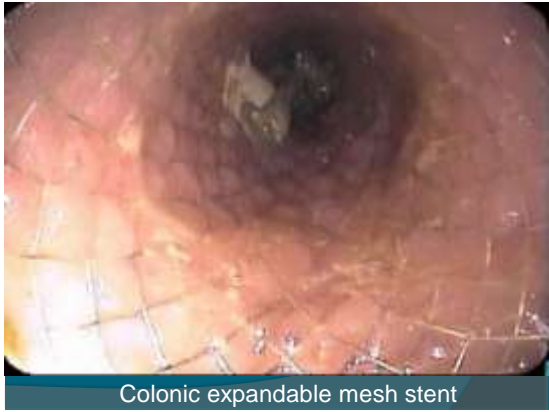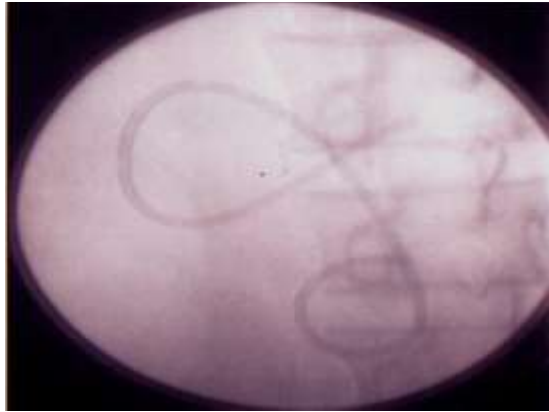
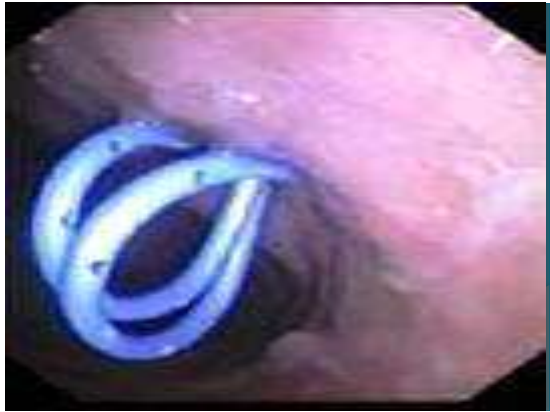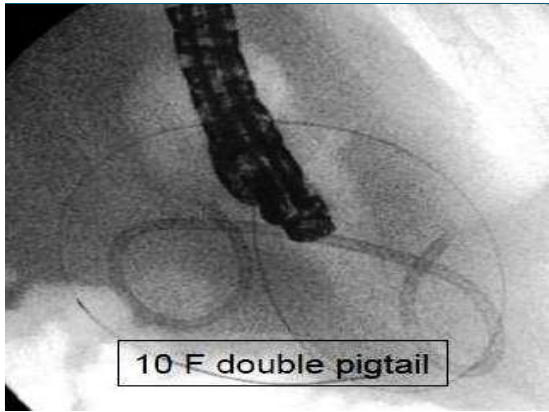
**Role of stent type**


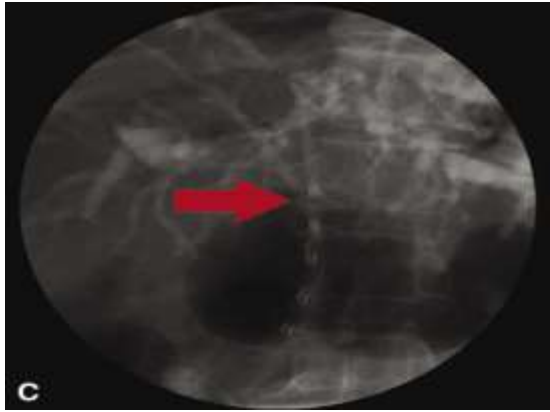
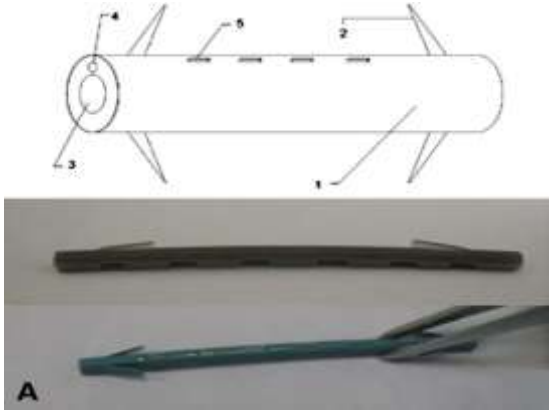
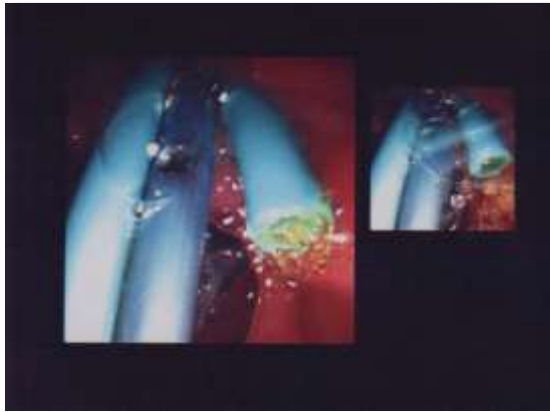
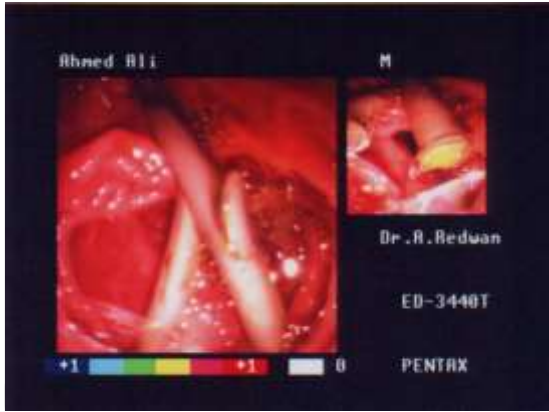
- At least two double pigtail
- 7 F sufficient ? or 10 Fr. ?
- Pigtail or straight ?
- Metal stent ?

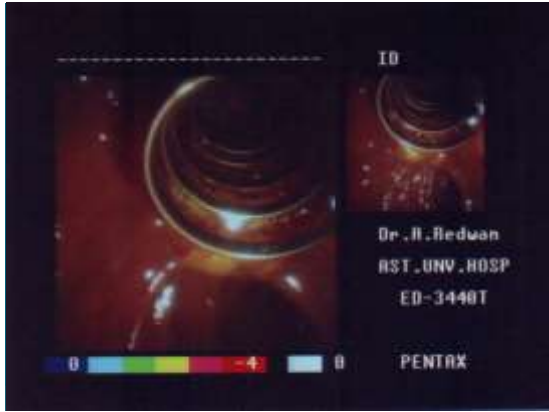
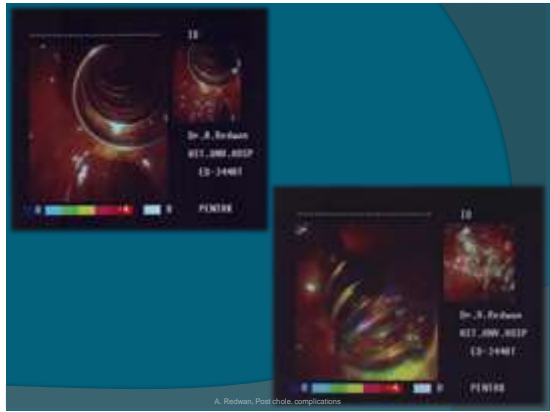
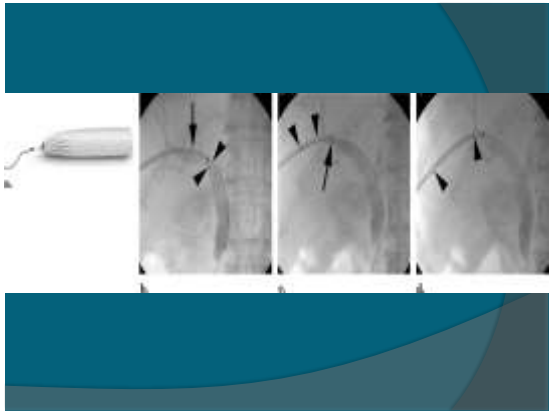
Barber N et al. *Gastrointestinal Clin Biol* 2008  
Gwynne et al. *GI Clin N Am* 2010

Reisner S et al. *Dis Colon Rectum* 2006  
Arvanitaki et al. *ISG* 2007

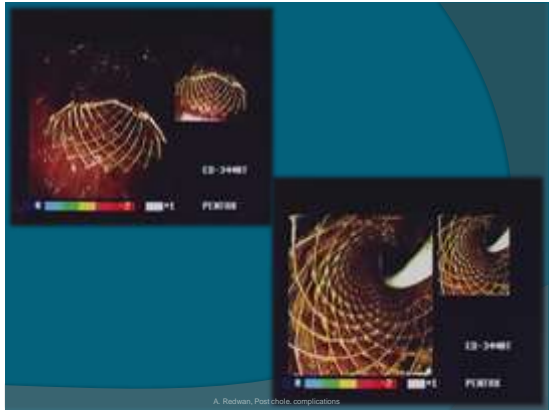




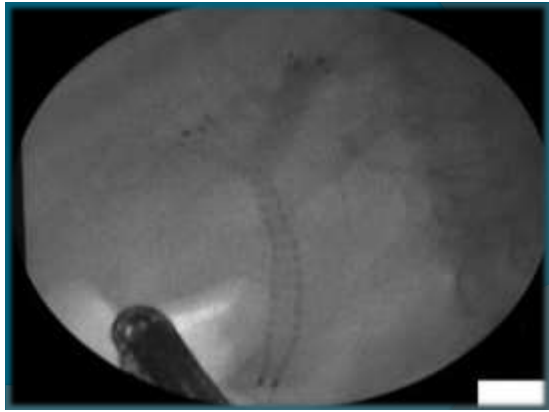





A. Redwan, Post chole. complications



A. Redwan, Post chole. complications



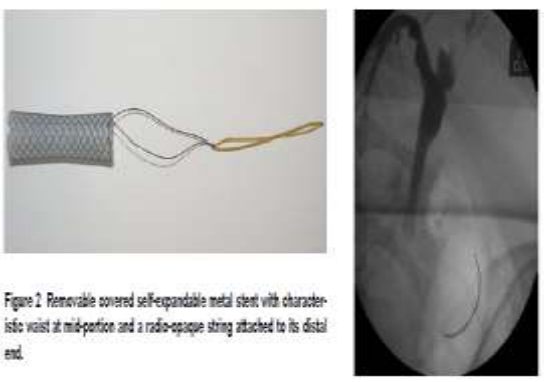


Figure 2 Removable covered self-expanding metal stent with characteristic waist at mid-portice and a radio-opaque string attached to its distal end.

### Stent Insertion Results

- Technical success rate for all types of SEMS is close to 90%
- Procedural mortality rate very low (0–1.4%)
- Perforations and fistulae uncommon

### Plastic Prosthesis vs Stents

- metal stents provide better palliation than plastic stents in esophageal cancer
  - Knyrim K A N Engl J Med 1993;329
  - De Palma DG Gastrointest Endosc 1996;43
  - Siersema PD Gastrointest Endosc 1998;47
  - Roseveare CD Eur J Gastroenterol Hepatol 1998;10
  - Sanyika C S Afr Med J 1999;89

# Complications

